

# Emergency department management of patients with adult congenital heart disease: a consensus paper from the ESC Working Group on Adult Congenital Heart Disease, the European Society for Emergency Medicine (EUSEM), the European Association for Cardio-Thoracic Surgery (EACTS), and the Association for Acute Cardiovascular Care (ACVC)

**Massimo Chessa** <sup>1,2,3,\*†</sup>, **Margarita Brida** <sup>2,3,4†</sup>, **Michael A Gatzoulis**<sup>2,3,5</sup>, **Gerhard-Paul Diller** <sup>2,3,6</sup>, **Jolien W Roos-Hesselink** <sup>2,3,7</sup>, **Konstantinos Dimopoulos** <sup>2,3,5</sup>, **Wilhelm Behringer**<sup>8,9</sup>, **Martin Möckel**<sup>9,10</sup>, **Alessandro Giamberti** <sup>11,12</sup>, **Lorenzo Galletti** <sup>12,13</sup>, **Susana Price**<sup>14,15</sup>, **Helmut Baumgartner** <sup>2,3,6</sup>, **Pastora Gallego** <sup>2,3,16</sup>, and **Oktay Tutarel** <sup>2,3,17†</sup>

<sup>1</sup>ACHD Unit, Pediatric and Adult Congenital Heart Centre, IRCCS Policlinico San Donato, Milan, Italy; <sup>2</sup>DZHK (German Centre for Cardiovascular Research), partner site Munich Heart Alliance, Munich, Germany; <sup>3</sup>European Society of Cardiology Working Group on Adult Congenital Heart Disease; <sup>4</sup>Division for Adult Congenital Heart Disease, Department of Cardiovascular Medicine, University Hospital Centre Zagreb, Zagreb, Croatia; <sup>5</sup>Adult Congenital Heart Centre and National Centre for Pulmonary Hypertension, Royal Brompton & Harefield NHS Trust, National Heart and Lung Institute, Imperial College, London, UK; <sup>6</sup>Department of Cardiology III: Adult Congenital and Valvular Heart Disease, University Hospital Muenster, Muenster, Germany; <sup>7</sup>Department of Cardiology, Thoraxcenter, Erasmus Medical Center, Rotterdam, The Netherlands; <sup>8</sup>Emergency Department, Center for Emergency Medicine, University Hospital Jena, Friedrich Schiller University, Am Klinikum 1, Jena, Germany; <sup>9</sup>European Society for Emergency Medicine; <sup>10</sup>Division of Emergency Medicine and Department of Cardiology, Charité- Universitätsmedizin Berlin, Berlin, Germany; <sup>11</sup>Department of Congenital Cardiac Surgery, IRCCS Policlinico San Donato, Milan, Italy; <sup>12</sup>European Association for Cardio-Thoracic Surgery; <sup>13</sup>Department of Cardiac Surgery, Bambino Gesù Hospital, Rome, Italy; <sup>14</sup>Royal Brompton Hospital, Adult Intensive Care Unit, London, UK; <sup>15</sup>Association for Acute Cardiovascular Care of the European Society of Cardiology; <sup>16</sup>Unidad de Cardiopatías Congénitas del Adulto, Hospital Virgen del Rocío, Sevilla, Spain; and <sup>17</sup>Department of Congenital Heart Disease and Paediatric Cardiology, German Heart Centre Munich, TUM School of Medicine, Technical University of Munich, Germany

Received 27 November 2020; revised 3 March 2021; editorial decision 13 April 2021; accepted 21 April 2021

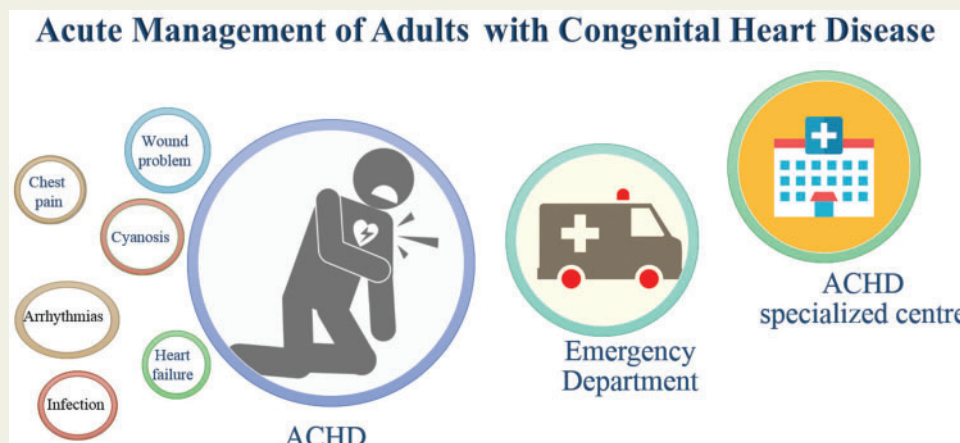
Adult congenital heart disease (ACHD) patients represent a growing population with increasing use of acute emergency department (ED) care. Providing comprehensive ED care necessitates an understanding of the most common clinical scenarios to improve morbidity and mortality in this population. The aim of this position document is to provide a consensus regarding the management of the most common clinical scenarios of ACHD patients presenting to the ED.

\* Corresponding author. Tel: +39-0252774528, Fax: +39-0252774459, Email: [massimo.chessa@grupposandonato.it](mailto:massimo.chessa@grupposandonato.it); [massichessa@yahoo.it](mailto:massichessa@yahoo.it)

†These authors contributed equally to this manuscript.

Published on behalf of the European Society of Cardiology. All rights reserved. © The Author(s) 2021. For permissions, please email: [journals.permissions@oup.com](mailto:journals.permissions@oup.com).

## Graphical Abstract



Adult congenital heart disease (ACHD) patients represent a growing population with increasing use of acute emergency department (ED) care. Providing comprehensive ED care necessitates an understanding of the most common clinical scenarios to improve morbidity and mortality in this population. The aim of this position document is to provide a consensus regarding the management of the most common clinical scenarios of ACHD patients presenting to the ED.

## Keywords

Congenital heart disease • Adult • Emergency • Multidisciplinary management

## Introduction

Despite a marked improvement in the survival and overall life expectancy of children born with congenital heart disease (CHD), the majority of those that became adults [adult congenital heart disease (ACHD)] suffer from residua of their primary cardiac defect and clinical sequelae, independent of prior surgical or transcatheter interventions. Consequently, ACHD is associated with a high rate of healthcare utilization, which in an ideal world should take place at dedicated medical centres with clinical expertise in the field.<sup>1-3</sup> Nonetheless, fragmentation of care remains a concern, especially when acute symptoms occur and patients present to the nearest hospital with an emergency department (ED). Large variations in ED infrastructure as well as acute cardiac care and emergency medicine practice exist even in countries with advanced healthcare systems.<sup>4,5</sup> Currently, no international recommendations exist regarding the emergency care of ACHD patients. Therefore, the aim of this position document is to provide a consensus regarding the management of the most common acute clinical scenarios in ACHD, which are relevant for the ED.

Although many of the problems described in this paper are not unique to ACHD patients [e.g. arrhythmia or heart failure (HF)], they may be more common or require different management strategies than in non-ACHD patients. The recommendations provided are based on available evidence and expert opinion.

## Arrhythmias and syncope

### General remarks

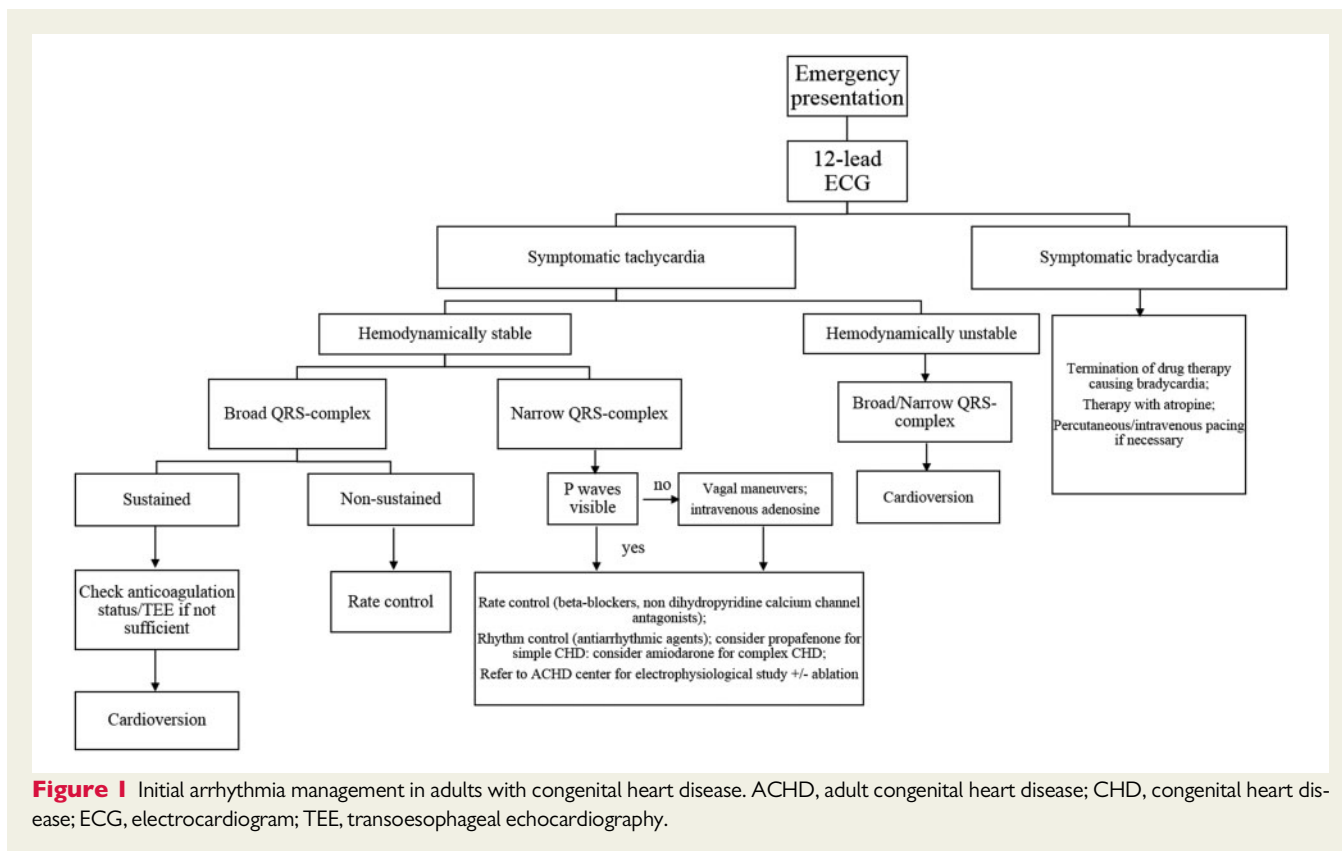
The most common emergency in ACHD is arrhythmia, accounting for 37% of emergency admissions.<sup>5</sup> Arrhythmias are also the most common cause for syncope in ACHD. However, other causes, such as pulmonary hypertension (PH) and neurologic causes, need to be excluded. The incidence and origin of arrhythmias vary depending on the complexity of disease, possible scar formation after reparative surgery and the presence of prosthetic material and residual lesions.

On presentation, patients should receive a 12-lead electrocardiogram (ECG) and device interrogation (if applicable) promptly.

In ACHD patients, differentiation between atrial and ventricular tachycardia (VT) may often be difficult due to a broad QRS complex and/or aberrant conduction. They should carry an electronic copy of their resting 12-lead ECG with them to share with the ED staff. In case of doubt, any broad complex tachycardia should be treated as ventricular in origin. Electrocardiogram documentation of the initial cardiac rhythm on admission prior to any antiarrhythmic drugs (such as amiodarone) or other medical interventions that reduce heart rate is paramount for subsequent electrophysiological assessment including amenability to ablation therapy.

### Atrial tachycardia

Atrial tachycardia (AT) is the most common arrhythmia in ACHD patients.<sup>6,7</sup> Sustained AT may lead to acute cardiac decompensation



**Figure 1** Initial arrhythmia management in adults with congenital heart disease. ACHD, adult congenital heart disease; CHD, congenital heart disease; ECG, electrocardiogram; TEE, transoesophageal echocardiography.

by rapid conduction through the atrioventricular node. Atrial tachycardia conducted 1:1 can potentially lead to syncope and sudden cardiac death (SCD).<sup>8</sup> If patients present in a haemodynamically unstable condition, immediate termination of AT with electrical or pharmacological cardioversion is necessary. Electrical cardioversion is the preferred choice in haemodynamically unstable conditions as it is more effective than pharmacological cardioversion. In contrast, in a haemodynamically stable situation, medical treatment and/or referral to a dedicated ACHD arrhythmia centre for an invasive approach is appropriate (Figure 1).

In selected, haemodynamically stable ACHD patients, after consultation with electrophysiology colleagues, accepting the persistence of AT (after medical heart rate reduction) is recommended to facilitate early electrophysiological ablation therapy with location of the underlying culprit lesion.

## Ventricular arrhythmias

Ventricular arrhythmias encompass monomorphic and polymorphic VTs as well as ventricular fibrillation (VF) and the incidence varies according to the underlying CHD. In patients with repaired tetralogy of Fallot (ToF), the incidence of VT has been reported as high as 14.6% whilst VF was documented in 0.5%.<sup>9</sup>

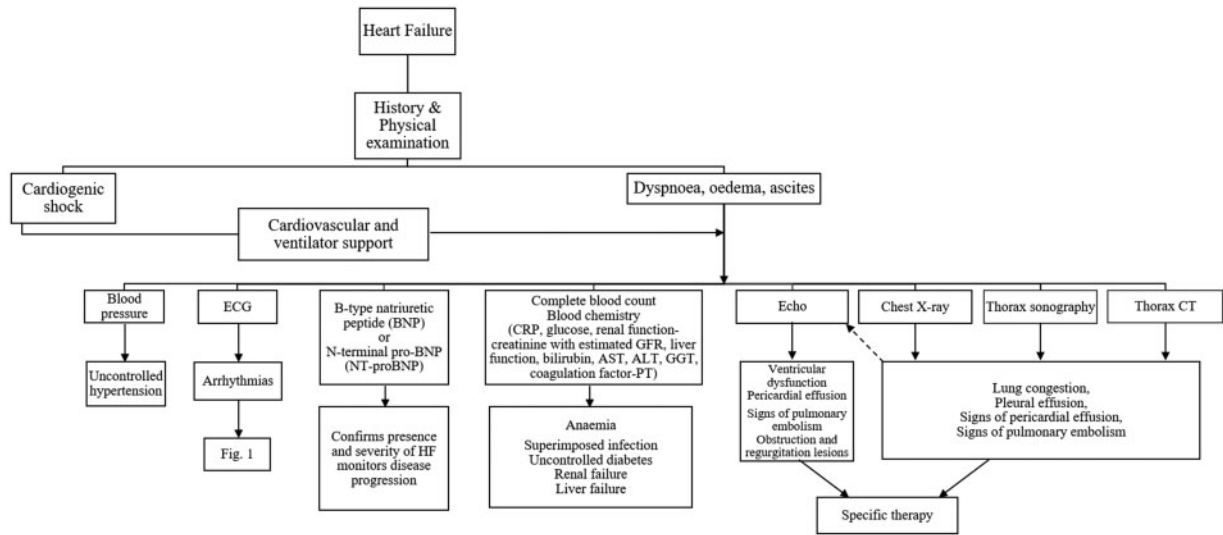
It is unclear whether improvements in surgical techniques and earlier management of VT risk factors such as right ventricular dilatation and dysfunction will reduce this incidence in the future. However,

nowadays malignant arrhythmias remain an issue for ToF patients and should be excluded when patients present with syncope.

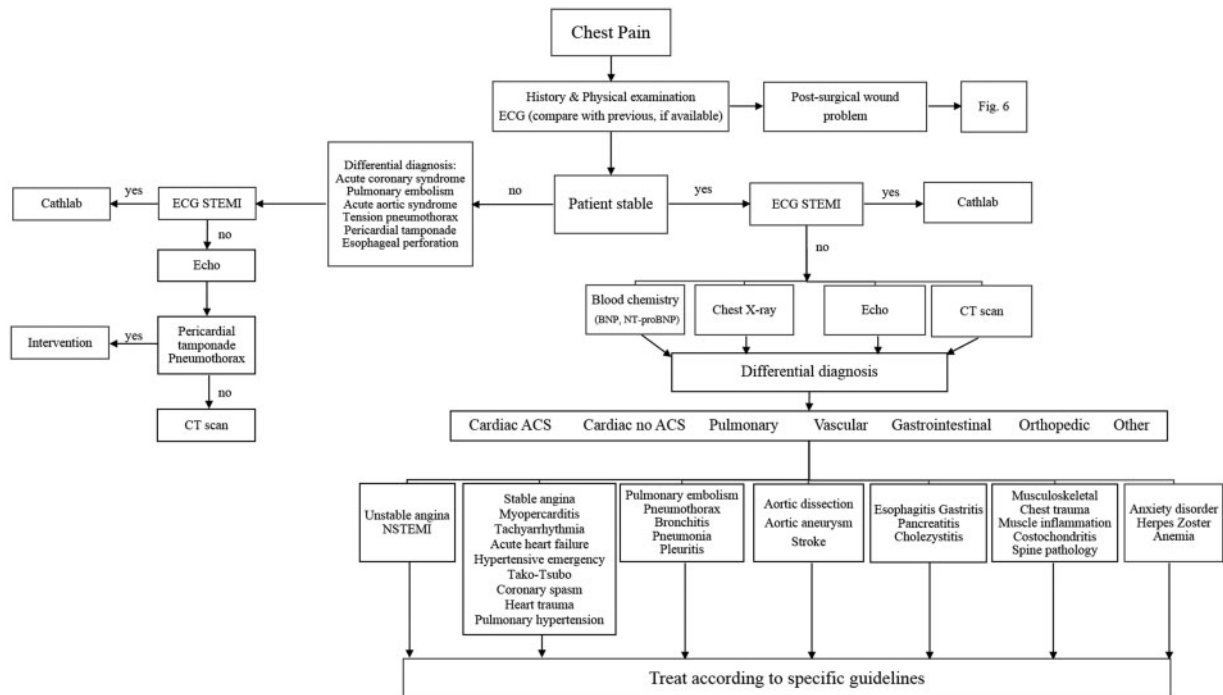
The incidence of VT, VF, and SCD increases with the complexity of CHD.<sup>10</sup> For acute termination of VT, electrical cardioversion is the treatment of choice. The most widely used antiarrhythmic drug in ACHD patients is amiodarone, which is also preferred in patients with structural heart disease (Figure 1).

## Bradyarrhythmias

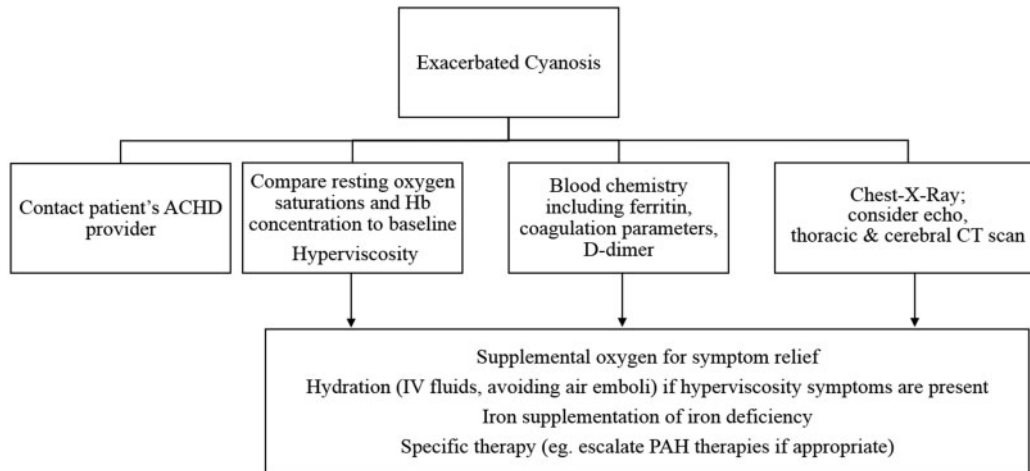
Bradycardias and high-degree atrioventricular block (AVB) may lead to syncope, HF due to low cardiac output or bradycardia-related ventricular arrhythmia (tachy-brady syndrome). Complete heart block is potentially a precursor of SCD.<sup>11</sup> Atrioventricular block is not uncommon in patients with atrioventricular septal defects and patients with congenitally corrected transposition of the great arteries.<sup>12</sup> Therefore, if a young adult presents with AVB, CHD should be excluded by echocardiography. In emergency situations, drug therapy with atropine and percutaneous/transvenous pacing should be initiated. Drugs leading to bradycardia should be discontinued (Figure 1). It is important to outline that in some ACHD patients (e.g. Fontan), a transvenous approach does not allow access to a ventricle and a retrograde transaortic approach may be required in the emergency setting, followed by epicardial pacing. Moreover, permanent transvenous pacing may increase the risk of systemic emboli in adults with intracardiac shunts (especially cyanotic patients).



**Figure 2** Heart failure management in adults with congenital heart disease. ALT, alanine aminotransferase; AST, aspartate aminotransferase; BNP, B-type natriuretic peptide; CRP, C-reactive protein; CT, computed tomography; ECG, electrocardiogram; Echo, transthoracic echocardiography; GFR, glomerular filtration rate; GGT, gamma-glutamyl transferase; NT-proBNP, N-terminal pro B-type natriuretic peptide; PT, prothrombin time.



**Figure 3** Management of chest pain in adults with congenital heart disease. ACS, acute coronary syndrome; BNP, B-type natriuretic peptide; CT, computed tomography; ECG, electrocardiogram; NSTEMI, non-ST-elevation myocardial infarction; NT-proBNP, N-terminal pro B-type natriuretic peptide; STEMI, ST-elevation myocardial infarction.



**Figure 4** Management of exacerbated cyanosis in adults with congenital heart disease. ACHD, adult congenital heart disease; CT, computed tomography; Hb, haemoglobin; IV, intravenous; PAH, pulmonary arterial hypertension.

## Heart failure

### General remarks

Common symptoms at presentation include acute or recent onset dyspnoea, peripheral oedema, ascites, and/or exercise intolerance, depending on the type of haemodynamic lesion and ventricular function. In patients presenting to the ED after recent surgery or interventions, late complications of the intervention/surgery should be excluded, including infection, pericardial or pleural effusions, dislocation of percutaneous devices, pacemaker dysfunction, etc.

### Assessment

In the emergency setting, physical examination, chest X-ray, and thoracic ultrasound are helpful in identifying lung congestion or infection, pleural effusions, and cardiomegaly. Echocardiography is essential to exclude a pericardial effusion, assess ventricular function, valve disease or obstructive lesions as well as PH; this should ideally be interpreted by an experienced ACHD operator, with good knowledge of the patient's background anatomy and history.

Management depends on past medical history, including primary diagnosis, previous interventions, residual lesion(s), and medication (including recent medication changes). Investigations to exclude precipitating factors like arrhythmia, arterial hypertension, pulmonary embolism, ischaemic heart disease, infection, anaemia, and thyroid dysfunction, are then tailored accordingly.

### Management

Medical management depends on the mechanisms precipitating HF and includes early cardioversion for arrhythmias, diuretics for symptom and oedema relief, vasodilators, inotropes, and, in more advanced cases, ventilatory and cardiovascular support (e.g. venous-arterial extracorporeal membrane oxygenation) for critical cardiovascular decompensation and shock (Figure 2).<sup>13,14</sup>

Patients presenting in cardiogenic shock require immediate support based on the ABC protocol (protecting airway, breathing, and

circulation), while other investigations are performed and ACHD expertise is sought. Arrangements should be made to transfer patients to a tertiary ACHD centre with possibilities for circulatory support, as soon as possible.

## Chest pain

### General remarks and assessment

All ACHD patients presenting to the ED with chest pain need careful evaluation that should include a thorough medical history, including the type and location of pain, physical examination, ECG, and echocardiography. Computed tomography (CT) or other advanced imaging may also be required. The differential diagnosis should include myocardial ischaemia, aortic dissection, pulmonary embolism, PH as well as lung infections. Coronary compression often presents with recurrent chest pain on effort, which may be typical or atypical and difficult to interpret in the presence of other significant symptoms or severe exercise limitation.

### Coronary anomalies

Abnormal coronary anatomy can be present, e.g. in patients with a systemic right ventricle (Mustard/Senning operation for transposition of the great arteries or congenitally corrected transposition) resulting in an imbalance between myocardial perfusion and oxygen demand. The right ventricle is supported by only one coronary artery and the demand is markedly increased due to hypertrophy and dilatation of the systemic right ventricle.<sup>15</sup> Abnormal coronary anatomy is also encountered in other types of CHD.

Furthermore, previous surgery (e.g. ToF correction, arterial switch for transposition of the great arteries, Ross operation, David operation, correction of anomalous origin of the left or right coronary artery from the pulmonary artery, etc.), may have caused coronary artery injury, and some patients may be at higher risk of developing coronary problems. Coronary angiography (invasive or CT) plays an

important role in the management of ACHD patients presenting with chest pain. It is helpful in excluding atherosclerotic disease, coronary anomalies as well as coronary complications related to previous surgery, albeit tertiary expertise may be required for interpretation.

### Other causes

The risk of aortic dissection is elevated not only in patients with Marfan syndrome or other hereditary thoracic aortic syndromes (high risk) but also in patients with a bicuspid aortic valve (lower risk).<sup>16</sup> The risk of thromboembolism, including pulmonary emboli, is increased in patients with a Fontan operation and in other complex and/or cyanotic CHD. Furthermore, rare late complications after interventional procedures like erosion of an atrial septal defect occluder can occur.

Pulmonary hypertension can also be the cause of chest pain. Both pulmonary arterial hypertension (PAH) and elevated pulmonary pressures due to systemic ventricular dysfunction or valve disease should be included in the differential diagnosis (Figure 3).

## Pulmonary arterial hypertension

### General remarks

Between 5% and 10% of ACHD patients have PH, either post-capillary (due to left heart disease) or less commonly pre-capillary (PAH).<sup>17,18</sup>

### Symptoms

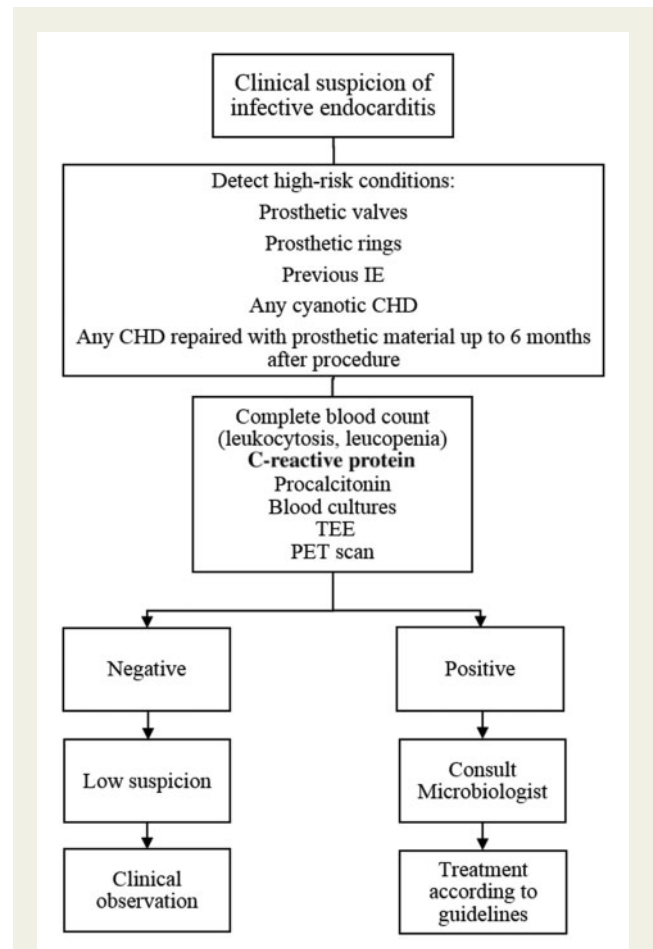
Patients with PAH related to CHD (PAH-CHD) can present acutely with a variety of symptoms, including syncope, haemoptysis, HF, palpitations, and chest pain.

Syncope on effort reflects their inability to increase pulmonary blood flow and cardiac output adequately and is a sign of advanced or advancing PAH disease. Precipitants may include ventricular or supra-ventricular arrhythmia (in patients with impaired right ventricular function), dehydration, medication, excessive effort, pregnancy, and infection.<sup>19,20</sup>

Haemoptysis in PAH patients can be mild to severe and can become life-threatening, requiring volume repletion, correction of clotting factors, maintaining appropriate haemoglobin levels, as well as advanced resuscitation with cardiovascular and respiratory support.

### Management

Patients with haemoptysis should be turned lying on the side of the bleeding lung and dual lumen or deep endotracheal intubation may be required to protect the unaffected lung. Angiography may be useful with selective vessel closure when relevant bleeding does not stop spontaneously. Patients presenting with severe HF or cardiogenic shock (e.g. due to a PH crisis or advanced PAH) may require advanced cardiorespiratory support and/or treatment with inotropes and pulmonary vasodilators (e.g. nitric oxide and/or intravenous epoprostenol), with careful adjustment of central venous pressure to optimize cardiac output. Noradrenaline may be needed in case of hypotension to maintain myocardial perfusion. Pulmonary arterial hypertension therapies should never be interrupted suddenly, especially parenteral prostanoids, because this can lead to a sudden



**Figure 5** Suggested algorithm for suspected infective endocarditis in adults with congenital heart disease. CHD, congenital heart disease; IE, infective endocarditis; PET, positron emission tomography; TEE, transoesophageal echocardiography.

deterioration (PH crisis); in PAH patients presenting with a broken indwelling line, or other line complication, intravenous prostanoids should be switched promptly to a peripheral or alternative central access.<sup>21,22</sup>

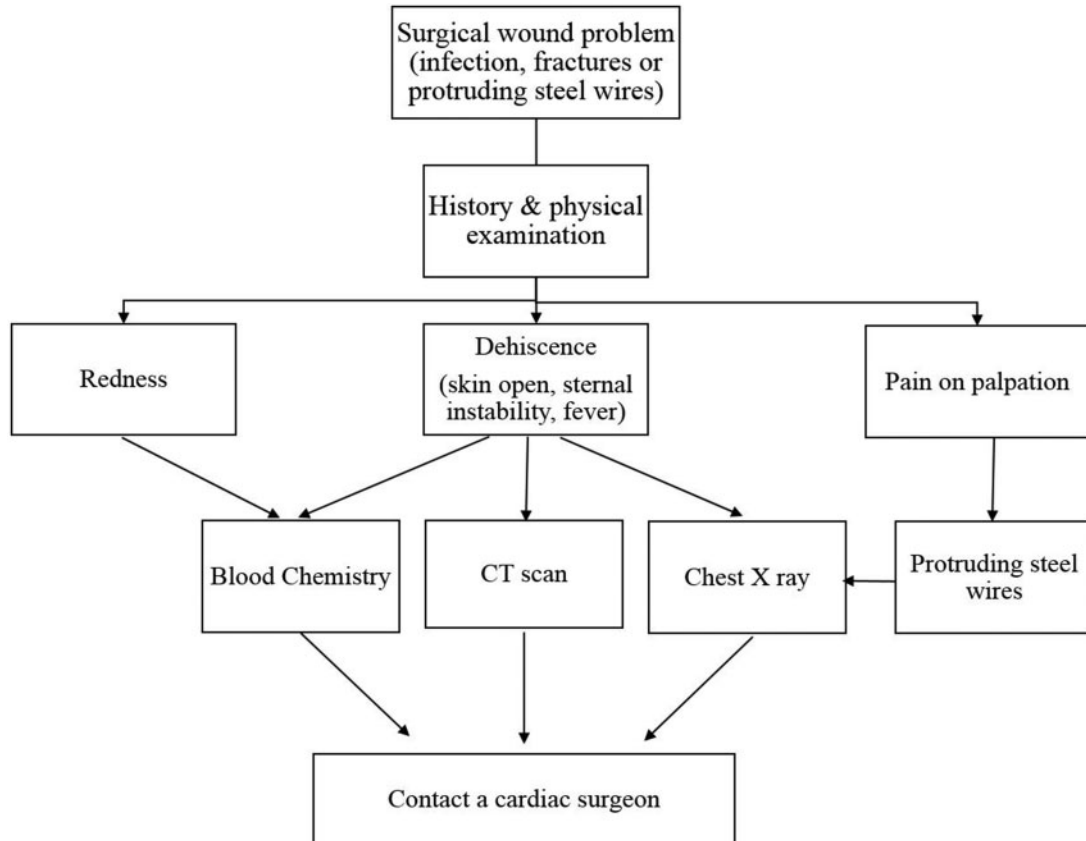
## Cyanosis

### General remarks

Cyanosis is typically present in CHD patients with an unrepaired or palliated defect (e.g. univentricular circulation, ToF), PAH with shunt reversal (Eisenmenger syndrome), right-to-left shunting in the presence of raised right ventricular filling pressures and an atrial communication (e.g. pulmonary stenosis or Ebstein's anomaly) or a fenestrated Fontan circulation. Long-standing cyanosis can cause or exacerbate elevated haemoglobin levels, exercise intolerance, multi-organ dysfunction and allow paradoxical embolism or a cerebral abscess (Figure 4).<sup>23,24</sup>

In patients with a Fontan circulation, rapidly progressive cyanosis may reflect a rise in total lung resistance due to thrombi in the Fontan





**Figure 6** Suggested algorithm for surgical wound problems in adults with congenital heart disease. CT, computed tomography.

circuit; in such cases, a CT scan may be necessary keeping in mind the different anatomy, which may require a different CT protocol (e.g. dual source of pulmonary blood flow in patients with a bidirectional Glenn anastomosis).<sup>25,26</sup>

## Management

All cyanotic patients should be aware of their baseline haemoglobin concentration and report this to the emergency staff, to aid in the interpretation of laboratory findings. They should also be aware of the need for intravenous line filters to avoid paradoxical air emboli. Finally, all cyanotic patients, with or without PH, are at increased risk of complications from invasive interventions, especially if general anaesthesia or sedation is required.

## Infection

### General remarks

The risk of infective endocarditis (IE) is substantially higher in ACHD patients compared to the general population, with marked variation in risk between lesions.<sup>27</sup> Congenital heart disease can also be part of the clinical spectrum of syndromes, such as functional asplenia in

heterotaxy (isomerism) and DiGeorge syndrome, commonly associated with immunodeficiency and, hence, susceptibility to systemic infections.

### Assessment

The diagnosis of IE is mainly based on history, imaging findings (echocardiography and in selected cases positron emission tomography–CT) and positive blood cultures (Figure 5).<sup>28</sup>

It should be kept in mind that IE in ACHD patients often affects the right heart structures (e.g. pulmonary valve and valve replacements, conduits, etc.). Furthermore, if an extracardiac infection has an unusual prolonged course, the possibility of secondary IE should be kept in mind. If an ACHD patient presents with signs of severe infection to the ED, the threshold for further investigations as well as contacting the regional ACHD centre should be low, and admission to hospital is often necessary. Antibiotics should be started as soon as two blood cultures are taken.

Especially, if a patient presents with signs of infection shortly after surgery, besides IE other possible diagnoses to consider are wound infections, lower respiratory tract infections, pleural effusions, and mediastinitis.

## Wound complications after surgery

### General remarks

Emergency department visits related to surgical wound problems are relatively rare, especially late after cardiac surgery. The most frequent causes are (i) wound infection, with or without mechanical sternal instability, (ii) sternal fractures, and (iii) problems related to protruding sternal wires. The main risk factor for the first two scenarios is diabetes, and additionally the use of a retraction device for exposure of internal mammary artery harvesting for the second scenario (rare in ACHD patients).<sup>29,30</sup>

### Assessment

The diagnosis of these problems can be made from a thorough review of the medical history and full physical examination. The inspection can reveal redness or dehiscence of the wound, pain on palpation, sternal crepitation indicating fracture, and the presence of protruding steel wires with or without a foreign body granuloma or skin perforation.

Sternal swab, blood tests including procalcitonin, C-reactive protein, and blood cultures in case of fever should be requested. Chest X-ray and thoracic CT scan are necessary in case of suspected mediastinitis, the presence of sternal crepitations, and in the case of protruding steel wire that may also cause cardiac tamponade. Patients should have an older photo of their wound on their mobile phone to share with the ED staff as a baseline.

### Management

In case of significant wound problem, prompt referral to cardiac surgery is recommended (ideally to the centre that performed surgery) (Figure 6).

## Conclusions

Adult congenital heart disease represents an important field with patients increasingly requiring acute ED care. Comprehensive ED management requires a profound understanding of the most common clinical scenarios, which in turn is paramount for improving morbidity and mortality in this growing adult patient population. Emergency department care providers should have basic ACHD training, follow current recommendations for initial management and should have direct access to ACHD tertiary advice (*Graphical abstract*).

### Acknowledgements

We thank Dr Carmelina Chiarello for her technical support.

**Conflict of interest:** Konstantinos Dimopoulos: Consultant and received educational and research grants from Janssen. Helmut Baumgartner: Edwards Lifesciences and Actelion: speaker fees and congress travel support.

### References

- Baumgartner H, Budts W, Chessa M, Deanfield J, Eicken A, Holm J, Iserin L, Meijboom F, Stein J, Szatmari A, Trindade PT, Walker F; for the Working Group on Grown-up Congenital Heart Disease of the European Society of Cardiology. Recommendations for organization of care for adults with congenital heart disease and for training in the subspecialty of 'Grown-up Congenital Heart Disease' in Europe: a position paper of the Working Group on Grown-up Congenital Heart Disease of the European Society of Cardiology. *Eur Heart J* 2014;**35**: 686–690.
- Mackie AS, Pilote L, Ionescu-Iltu R, Rahme E, Marelli AJ. Health care resource utilization in adults with congenital heart disease. *Am J Cardiol* 2007;**99**:839–843.
- Verheugt CL, Uiterwaal CS, van der Velde ET, Meijboom FJ, Pieper PG, Sieswerda GT, Plokker HW, Grobbee DE, Mulder BJ. The emerging burden of hospital admissions of adults with congenital heart disease. *Heart* 2010;**96**: 872–878.
- Agarwal S, Sud K, Khara S, Kolte D, Fonarow GC, Panza JA, Menon V. Trends in the burden of adult congenital heart disease in US Emergency Departments. *Clin Cardiol* 2016;**39**:391–398.
- Kaemmerer H, Bauer U, Pensl U, Oechslin E, Gravenhorst V, Franke A, Hager A, Balling G, Hauser M, Eicken A, Hess J. Management of emergencies in adults with congenital cardiac disease. *Am J Cardiol* 2008;**101**:521–525.
- Hernandez-Madrid A, Paul T, Abrams D, Aziz PF, Blom NA, Chen J, Chessa M, Combes N, Dagnes N, Diller G, Ernst S, Giamberti A, Hebe J, Janousek J, Kriebel T, Moltedo J, Moreno J, Peinado R, Pison L, Rosenthal E, Skinner JR, Zeppenfeld K; ESC Scientific Document Group. Arrhythmias in congenital heart disease: a position paper of the European Heart Rhythm Association (EHRA), Association for European Paediatric and Congenital Cardiology (AEPC), and the European Society of Cardiology (ESC) Working Group on Grown-up Congenital Heart Disease, endorsed by HRS, PACES, APHRS, and SOLAECE. *Europace* 2018;**20**: 1719–1753.
- Bouchardy J, Therrien J, Pilote L, Ionescu-Iltu R, Martucci G, Bottega N, Marelli AJ. Atrial arrhythmias in adults with congenital heart disease. *Circulation* 2009;**120**:1679–1686.
- Franco E, Sanchez I, Vazquez Martinez JL, Moreno J. Ventricular fibrillation caused by 1:1 atrial flutter. *J Cardiovasc Electrophysiol* 2016;**27**:1488–1489.
- Khairy P, Aboulhosn J, Gurvitz MZ, Opatowsky AR, Mongeon FP, Kay J, Valente AM, Earing MG, Lui G, Gersony DR, Cook S, Ting JG, Nickolaus MJ, Webb G, Landzberg MJ, Broberg CS; Alliance for Adult Research in Congenital Cardiology (AARCC). Arrhythmia burden in adults with surgically repaired tetralogy of Fallot: a multi-institutional study. *Circulation* 2010;**122**:868–875.
- Koyak Z, Harris L, de Groot JR, Silversides CK, Oechslin EN, Bouma BJ, Budts W, Zwinderman AH, Van Gelder IC, Mulder BJ. Sudden cardiac death in adult congenital heart disease. *Circulation* 2012;**126**:1944–1954.
- Hokanson JS, Moller JH. Significance of early transient complete heart block as a predictor of sudden death late after operative correction of tetralogy of Fallot. *Am J Cardiol* 2001;**87**:1271–1277.
- Baruteau AE, Pass RH, Thambo JB, Behaghel A, Le Penne S, Perdreau E, Combes N, Liberman L, McLeod CJ. Congenital and childhood atrioventricular blocks: pathophysiology and contemporary management. *Eur J Pediatr* 2016;**175**: 1235–1248.
- Brida M, Diller GP, Nashat H, Strozzi M, Milicic D, Baumgartner H, Gatzoulis MA. Pharmacological therapy in adult congenital heart disease: growing need, yet limited evidence. *Eur Heart J* 2019;**40**:1049–1056.
- Mebazaa A, Yilmaz MB, Levy P, Ponikowski P, Peacock WF, Laribi S, Ristic AD, Lambrinou E, Masip J, Riley JP, McDonagh T, Mueller C, deFilippi C, Harjola VP, Thiele H, Piepoli MF, Metra M, Maggioni A, McMurray JJ, Dickstein K, Damman K, Seferovic PM, Ruschitzka F, Leite-Moreira AF, Bellou A, Anker SD, Filippatos G. Recommendations on pre-hospital and early hospital management of acute heart failure: a consensus paper from the Heart Failure Association of the European Society of Cardiology, the European Society of Emergency Medicine and the Society of Academic Emergency Medicine—short version. *Eur Heart J* 2015;**36**:1958–1966.
- Brida M, Diller GP, Gatzoulis MA. Systemic right ventricle in adults with congenital heart disease: anatomic and phenotypic spectrum and current approach to management. *Circulation* 2018;**137**:508–518.
- Erbel R, Aboyans V, Boileau C, Bossone E, Bartolomeo RD, Eggebrecht H, Evangelista A, Falk V, Frank H, Gaemperli O, Grabenwöger M, Haverich A, Iung B, Manolis AJ, Meijboom F, Nienaber CA, Roffi M, Rousseau H, Sechtem U, Sirnes PA, Allmen RS, Vrints CJ. 2014 ESC Guidelines on the diagnosis and treatment of aortic diseases: document covering acute and chronic aortic diseases of the thoracic and abdominal aorta of the adult. The Task Force for the Diagnosis and Treatment of Aortic Diseases of the European Society of Cardiology (ESC). *Eur Heart J* 2014;**35**:2873–2926.
- Dimopoulos K, Condliffe R, Tulloh RMR, Clift P, Alonso-Gonzalez R, Bedair R, Chung NAY, Coghlan G, Fitzsimmons S, Frigiola A, Howard LS, Jenkins P, Kenny D, Li W, MacDonald ST, McCabe C, Oliver JJ, Spence MS, Sathanthar GV, von Klemperer K, Wilson DG, Wort SJ; CHAMPION Steering Committee. Echocardiographic screening for pulmonary hypertension in congenital heart disease: JACC review topic of the week. *J Am Coll Cardiol* 2018;**72**:2778–2788.



18. Brida M, Gatzoulis MA. Pulmonary arterial hypertension in adult congenital heart disease. *Heart* 2018;**104**:1568–1574.
19. Drakopoulou M, Nashat H, Kempny A, Alonso-Gonzalez R, Swan L, Wort SJ, Price LC, McCabe C, Wong T, Gatzoulis MA, Ernst S, Dimopoulos K. Arrhythmias in adult patients with congenital heart disease and pulmonary arterial hypertension. *Heart* 2018;**104**:1963–1969.
20. Li Q, Dimopoulos K, Liu T, Xu Z, Liu Q, Li Y, Zhang J, Gu H. Peripartum outcomes in a large population of women with pulmonary arterial hypertension associated with congenital heart disease. *Eur J Prev Cardiol* 2019;**26**:1067–1076.
21. Price LC, Dimopoulos K, Marino P, Alonso-Gonzalez R, McCabe C, Kempny A, Swan L, Boutsikou M, Al Zahrani A, Coghlan GJ, Schreiber BE, Howard LS, Davies R, Toshner M, Pepke-Zaba J, Church AC, Peacock A, Corris PA, Lordan JL, Gaine S, Condliffe R, Kiely DG, Wort SJ. The CRASH report: emergency management dilemmas facing acute physicians in patients with pulmonary arterial hypertension. *Thorax* 2017;**72**:1035–1045.
22. D'Alto M, Constantine A, Balint OH, Romeo E, Argiento P, Ablonczy L, Skoro-Sajer N, Giannakoulas G, Dimopoulos K. The effects of parenteral prostacyclin therapy as add-on treatment to oral compounds in Eisenmenger syndrome. *Eur Respir J* 2019;**54**:1901401.
23. Rychik J, Atz AM, Celermajor DS, Deal BJ, Gatzoulis MA, Gewillig MH, Hsia T-Y, Hsu DT, Kovacs AH, McCrindle BW, Newburger JW, Pike NA, Rodefeld M, Rosenthal DN, Schumacher KR, Marino BS, Stout K, Veldtman G, Younoszai AK, d'Udekem Y; On behalf of the American Heart Association Council on Cardiovascular Disease in the Young and Council on Cardiovascular and Stroke Nursing. Evaluation and management of the child and adult with fontan circulation: a scientific statement from the American Heart Association. *Circulation* 2019;**140**:e234–e284.
24. Rodriguez FH, Book WM. Management of the adult Fontan patient. *Heart* 2020;**106**:105–110.
25. Dimopoulos K, Wort SJ, Gatzoulis MA. Pulmonary hypertension related to congenital heart disease: a call for action. *Eur Heart J* 2014;**35**:691–700.
26. Diller GP, Kempny A, Inuzuka R, Radke R, Wort SJ, Baumgartner H, Gatzoulis MA, Dimopoulos K. Survival prospects of treatment naive patients with Eisenmenger: a systematic review of the literature and report of own experience. *Heart* 2014;**100**:1366–1372.
27. Baumgartner H, De Backer J, Babu-Narayan SV, Budts W, Chessa M, Diller GP, Lung B, Kluin J, Lang IM, Meijboom F, Moons P, Mulder BJM, Oechslin E, Roos-Hesselink JW, Schwerzmann M, Sondergaard L, Zeppenfeld K; ESC Scientific Document Group. 2020 ESC Guidelines for the management of adult congenital heart disease. *Eur Heart J* 2021;**42**:563–645.
28. Habib G, Lancellotti P, Antunes MJ, Bongiorni MG, Casalta JP, Del Zotti F, Dulgheru R, El Khoury G, Erba PA, lung B, Miro JM, Mulder BJ, Plonska-Gosciniak E, Price S, Roos-Hesselink J, Snygg-Martin U, Thuny F, Tornos Mas P, Vilacosta I, Zamorano JL; ESC Scientific Document Group. 2015 ESC Guidelines for the management of infective endocarditis: the Task Force for the Management of Infective Endocarditis of the European Society of Cardiology (ESC). Endorsed by: European Association for Cardio-Thoracic Surgery (EACTS), the European Association of Nuclear Medicine (EANM). *Eur Heart J* 2015;**36**:3075–3128.
29. Moore R, Follette DM, Berkoff HA. Poststernotomy fractures and pain management in open cardiac surgery. *Chest* 1994;**106**:1339–1342.
30. Stahle E, Tammelin A, Bergstrom R, Hambreus A, Nystrom SO, Hansson HE. Sternal wound complications—incidence, microbiology and risk factors. *Eur J Cardiothorac Surg* 1997;**11**:1146–1153.